

# Arthroscopic Treatment of Hip Chondral Defects: Autologous Chondrocyte Transplantation Versus Simple Debridement—A Pilot Study

Andrea Fontana, M.D., Alessandro Bistolfi, M.D., Maurizio Crova, M.D.,  
Federica Rosso, M.D., and Giuseppe Massazza, M.D.

---

**Purpose:** To compare the effectiveness of simple arthroscopic debridement versus arthroscopic autologous chondrocyte transplantation (ACT) for the treatment of hip chondral lesions. **Methods:** We carried out a controlled retrospective study of 30 patients affected by a post-traumatic hip chondropathy of the third or fourth degree, according to the Outerbridge classification, measuring 2 cm<sup>2</sup> in area or more. Of these patients, 15 underwent arthroscopic ACT, whereas the other 15 underwent arthroscopic debridement. The 2 groups were similar in age, sex, degree, and location of the pathology. All the patients were assessed before and after the procedure with the Harris Hip Score (HHS). **Results:** In both groups the mean follow-up was approximately 74 months (range, 72 to 76 months). The mean size of the defect was 2.6 cm<sup>2</sup>. The patients who underwent ACT (group A) improved after the procedure compared with the group that underwent debridement alone (group B). The mean HHS preoperatively was 48.3 (95% confidence interval [CI], 45.4 to 51.2) in group A and 46 (95% CI, 42.7 to 49.3) in group B ( $P = .428$  [no significant difference]). The final HHS was 87.4 (95% CI, 84.3 to 90.5) in group A and 56.3 (95% CI, 54.4 to 58.7) in group B ( $P < .001$  [significant difference]). **Conclusions:** This study indicates that an ACT procedure can be used in the hip for acetabular chondral defects. **Level of Evidence:** Level III, retrospective comparative study.

---

After the initial experiences with arthrotomy techniques, several arthroscopic techniques were developed for the treatment of chondral lesion in the knee joint.<sup>1-4</sup> Among these, autologous chondrocyte transplantation (ACT) with a 2-step technique has led to good clinical results.<sup>5,6</sup> New techniques based on

biodegradable scaffolds have been developed to avoid the periosteal flap.<sup>7-10</sup> Several materials have been proposed as matrices to deliver the chondrocytes to the cartilage defect and to provide mechanical support and nutrition to the cells: protein-based polymers, carbohydrate polymers, and artificial polymers.<sup>11-14</sup> Cartilage lesions and chondral defects are also common in the hip after several traumatic and congenital pathologies.<sup>15-18</sup> Numerous studies have shown the direct association between acetabular labrum lesions and chondral lesions of the femoral head and acetabulum.<sup>19-24</sup>

Currently, there is growing interest in non-arthroplasty surgical treatment of chondropathies of the acetabulum and the femoral head because they are a frequent cause of pain and functional limitation. Usually, the treatment of hip cartilage lesions is based exclusively on arthroscopic debridement or microfractures,<sup>25-30</sup> and new different treatments have been proposed only recently, such as ar-

---

*From the Hip and Knee Unit (A.F.) and Biotechnologies Department (A.F.), Clinica Capitanio, Milan; Department of Orthopaedics, Traumatology and Health Medicine, CTO/M. Adelaide Hospital (A.B., M.C., G.M.), Turin; and Department of Orthopaedics, Traumatology and Health Medicine, University of Turin (M.C., F.R., G.M.), Turin, Italy.*

*The authors report no conflict of interest.*

*Received January 9, 2011; accepted August 22, 2011.*

*Address correspondence to Alessandro Bistolfi, M.D., CTO/M. Adelaide Hospital, via Zuretti 29, 10126 Turin, Italy. E-mail: [alessandro.bistolfi@cto.to.it](mailto:alessandro.bistolfi@cto.to.it)*

*Crown Copyright © 2012 Published by Elsevier Inc. on behalf of the Arthroscopy Association of North America. All rights reserved.*

*0749-8063/1125/\$36.00*

*doi:10.1016/j.arthro.2011.08.304*

throscopic repair of acetabular chondral delamination with fibrin adhesive.<sup>31</sup>

This technique is based on previous studies of the knee,<sup>7-14</sup> which have led to the development of scaffolds as implants, used for the delivery of cultured cells. Arthroscopic treatment of chondral lesions in the hip may reduce the risks of avascular necrosis correlated to surgical dislocation. In addition, this technique makes it possible to avoid the periosteal cover, which—in our opinion—would be very difficult to introduce in the hip.

The purpose of this study was to compare arthroscopic ACT with simple arthroscopic debridement. The hypotheses were that arthroscopic ACT is better than debridement and that arthroscopic ACT is practical for chondral lesions in the hip joint.

## METHODS

### Patient Selection

From 1996 to 2004, we carried out 274 hip arthroscopies for treatment of chondral defects or hip pathologies. Before surgery, patients were examined with standard radiographs and magnetic resonance imaging (MRI). All 274 hips presented with pain clinically, reduction of range of motion, and signs of femoroacetabular conflict and/or labral lesions, as well as some pathology on radiographs or MRI, and were therefore subjected to hip arthroscopy after informed consent was obtained. Inclusion criteria for this study were signs of arthritis of the hip, including slightly reduced articular space on radiographs (Tonnis grade 2 [moderate], with small cysts, moderate narrowing of the joint space, and moderate loss of head sphericity), but we excluded cases with severely reduced articular space on radiographs (Tonnis grade 3 [severe], with large cysts, severe narrowing or obliteration of the joint space, and severe deformity of the head) and massive chondral lesions on MRI. We unilaterally decided to exclude grade 3 lesions because in these cases the arthritis is too advanced to yield benefits from arthroscopic treatment. Therefore the decision to include or exclude patients in the study was based on radiographs, MRI, and arthroscopy as the final step.

A total of 181 patients met the inclusion criteria; the others underwent different surgical treatments (synovectomy, hip replacement, simple removal of loose bodies, and so on). During arthroscopy, the cartilage damage was assessed according to the Outerbridge classification and localized on both the acetabulum and the femoral head in 3 areas: anterior, superior, and

posterior. The area of the cartilage lesion was also measured in square centimeters. The size of the lesion was evaluated arthroscopically by optical estimation based on our experience. In 37 of 181 patients with a similar chondral defect of the third or fourth degree, which extended 2 cm<sup>2</sup> or more, arthroscopic ACT was performed (representing 12.4% of the cases). The remaining 144 patients were treated by hip arthroscopy and simple debridement for chondral defects. Fifteen patients who completed follow-up of at least 6 years (range, 72 to 76 months) were chosen from the group that underwent ACT (group A). Among the 144 patients treated with the debridement, a second group of 15 patients was chosen to serve as the control group (group B). In determining the criteria used to select the patients in group B, our objective was to obtain 2 homogeneous groups in terms of age, sex, body mass index, and degree and area of the chondral lesion. Therefore group B included cases where the third- to fourth-degree chondral lesion, which extended 2 cm<sup>2</sup> or more, had been exclusively debrided, and the patients were similar to those in group A, who were treated with arthroscopic ACT. In both groups the hip arthroscopy procedure was indicated for persistent pain, reduced range of motion, and signs of acetabular conflict in association with radiographic signs of initial arthritis of the hip. Both groups were clinically assessed preoperatively and postoperatively with the Harris Hip Score (HHS). This study was approved by the local institutional review board.

### Surgical Technique

All arthroscopies were carried out with the patient in a lateral decubitus position and with combined longitudinal and inguinal traction applied. The hip was accessed by the superior trochanteric, anterior trochanteric, and posterior trochanteric portals for evaluation, biopsy, treatment, and implantation of the scaffold.

**Group A:** In those cases treated by ACT (group A), the surgical treatment was always carried out in 2 steps. The first step, diagnostic arthroscopy, was used to evaluate the chondral damage and to take a cartilage biopsy specimen from the area surrounding the pulvinar. Then, the transplant was implanted during the second step, operative arthroscopy, after approximately 30 days. First, a chondrectomy was always performed in the area affected by the chondropathy, by use of angled curettes or motorized shavers and exposure of the subchondral bone, to create clear margins between the healthy cartilage and the degenerated area. The chondrocyte culture was carried out on 1 of the bioresorbable two-component gel-polymer scaffolds

used at our institution: the BioSeed-C (BioTissue Technologies GmbH, Freiburg, Germany). The BioSeed is a reabsorbable composite material of a polymer-based scaffold ( $2 \times 3$  cm and 0.2 cm in height) of polyglycolic/polylactic acid (polyglactin, vicryl) and polydioxanone. It is used for the 3-dimensional growth of cultured chondrocytes and their implantation in transplant procedures. After the biopsy, the cells can be stored for up to 2 years. The cells were cultured at the cell processing facility of the manufacturer according to the state-of-the-art technique. Over a period of 3 to 5 weeks, they were cultured on a monolayer to increase to approximately 12 million cells. Then, the cells were incubated over the membrane for the 3-dimensional growth and stored before surgery for an approximate time of 2 to 6 weeks. Every step of the manufacturing process was monitored to ensure high quality and safety. The scaffold membrane with the chondrocytes was cut to exactly fit the chondral defect after its preparation and then rolled to pass along the cannula (Fig 1). Then, the transplant was inserted directly into the articular cavity through an arthroscopic cannula and was adapted to the chondral defect (Fig 2). After the implant had been positioned on the cartilage defect, traction was released and the articulation was subjected to a series of 5 extension and rotation movements. Afterward, traction was reapplied and the position of the transplant was controlled arthroscopically, to verify the fact that the transplant had remained in its position. The implantation and the arthroscopic evaluation that followed were performed without intra-articular fluid.

**Group B:** Patients in group B underwent a single surgery: once the chondral defect was identified, a chondrectomy was performed in the area affected by

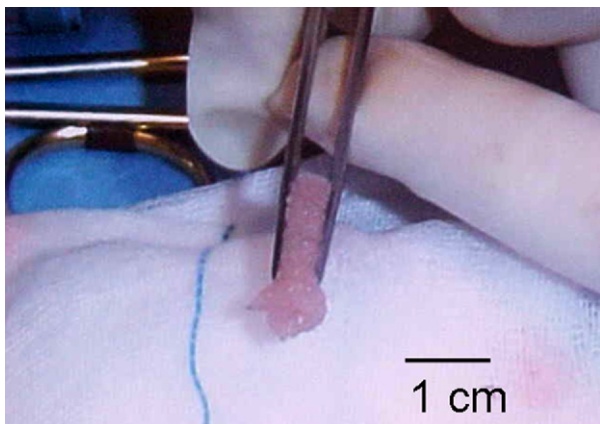


FIGURE 1. The membrane is rolled for insertion into the joint.

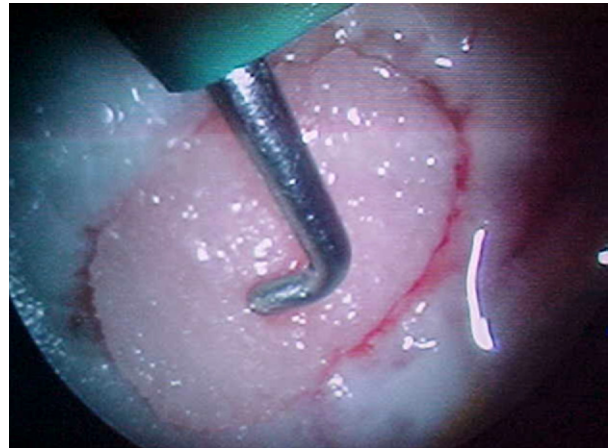

FIGURE 2. Arthroscopic view of membrane covering acetabular chondral defect. The fluid was stopped.

the chondropathy, again with angled curettes or motorized shavers. In this case an intra-articular debridement was associated and the chondrectomy was limited to the clearly damaged or detached cartilage, leaving in situ as much of the cartilage as possible. For this reason, the debridement may ultimately result in a smaller defect than occurs with preparation for ACT. The exposure of the subchondral bone was reduced to only the regions where it was strictly necessary to avoid conflicts or potential loose bodies.

### Postoperative and Rehabilitation Protocol

Postoperatively, the patients in group A and group B followed a similar standard rehabilitation program. Exercises began from the first postoperative day. Patients were discharged from the hospital on the second day and underwent both active and passive physiotherapy to regain complete range of motion without putting any weight on the articulation for 4 weeks. Partial load was allowed after 4 weeks in group A and after 2 weeks in group B. Exercises on a gym bike and swimming were recommended after 4 weeks in both groups. After 7 weeks, crutches were no longer required, and the patients were allowed to return to normal work activity. Jogging was allowed only after 6 months, whereas a complete return to sports activities was recommended only 1 year after the surgical procedure.

### Statistical Analysis

The analysis of variance test was used to test the statistical significance of the observed differences be-

TABLE 1. Comparison of Main Features in Groups A and B

	Group A	Group B	P Value
Mean age (range) (yr)	40.7 (22-52)	42.3 (20-53)	$P = .9353$
Sex	9 female/6 male	9 female/6 male	—
Acetabular defects	15 (anterior and superior areas)	15 (anterior and superior areas)	—
Femoral head defects	2 (superior area)	2 (superior area)	—
Kissing lesions (acetabular defects + femoral head defects)	1 (superior area)	2 (superior area)	—
Mean follow-up (range) (mo)	73.8 (72-76)	74.3 (72-76)	—

NOTE. The 2 groups were homogeneous.

tween preoperative evaluation and postoperative evaluation and between the 2 groups.  $P < .05$  was considered statistically significant. Confidence intervals (CIs) were also calculated by use of the Microsoft Excel program (Microsoft, Redmond, WA) with  $\alpha$  of .05, standard deviation, and casuistry dimension.

## RESULTS

### Patient Characteristics

The 2 groups were homogeneous for age, sex, and characteristics (size and grade) of the cartilage lesion, which are reported in Table 1. The mean extension of the cartilage defect identified during arthroscopy was 2.6 cm<sup>2</sup> (range, 2 to 3.4 cm<sup>2</sup> in group A and 2 to 3.2 cm<sup>2</sup> in group B). We had 2 cases of chondral defects on the femoral head in each group (approximately the same size): both cases in group B were kissing lesions, whereas 1 case in group A was a kissing lesion. The mean follow-up was 73.8 months (range, 72 to 76 months) in group A and 74.3 months (range, 72 to 76 months) in group B. None of the selected patients was lost to follow-up.

### Clinical Results

The preoperative mean total HHS was similar for the 2 groups: 48.3 for group A and 46 for group B, with  $P = .428$  (no statistical difference). The patients who underwent ACT improved after the procedure compared with the group that underwent debridement alone (Fig 3). At the last clinical evaluation (approximately 5 years), the patients in group A, treated with ACT, obtained a mean postoperative HHS of 87.4, which was higher than the mean HHS in group B patients, at 56.3. The difference between the 2 groups was statistically significant ( $P < .001$ ). Patients in group A had a statistically significant improvement between the preoperative score (mean, 42.3) and the

score at 6 months (mean, 82.6) ( $P < .001$ ), but the improvement was not statistically significant between 6 months (mean, 82.6) and 1 year (mean, 87) ( $P = .1455$ ). Similarly, patients in group B only improved in the first 6 months (mean score, 46.8 preoperatively v 59.1 at 6 months;  $P < .001$ ). The results in group A did not deteriorate between 1 and 5 years (Table 2). Group B showed no statistically significant differences between mean score at 1 year (58.6) and mean score at 5 years (56.5) ( $P = .4968$ ). In particular, there was not a difference in the decrease in group B at 5 years compared with the best value obtained at 6 months (mean score, 56.5 and 59.1, respectively;  $P = .2847$ ). In addition, there was not a statistically significant difference between the scores of the 2 groups preoperatively, but there was over the years (Table 2).

The score for the item "pain" (maximum score, 44) increased from a mean of 20 preoperatively in both groups ("moderate-intense" pain) to approximately 40 in group A and approximately 35 in group B. The score for the item "range of movement" did not change significantly between the 2 groups and did not

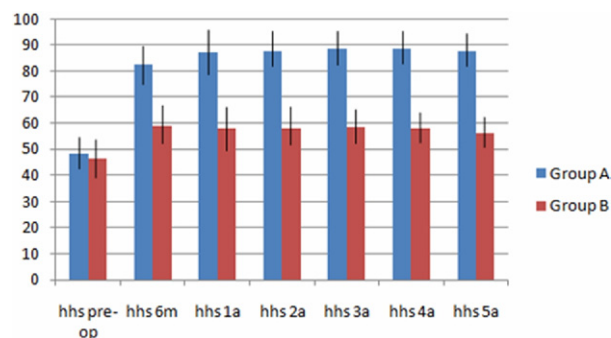


FIGURE 3. Results of HHS in groups A and B over time (mean  $\pm$  SD). (pre-op, preoperatively; 6m, 6 months postoperatively; 1a, 1 year postoperatively; 2a, 2 years postoperatively; 3a, 3 years postoperatively; 4a, 4 years postoperatively; 5a, 5 years postoperatively.)



**TABLE 2.** *HHS for Groups A and B During First 5 Years*

	Preoperative	Postoperative					
		6 mo	1 yr	2 yr	3 yr	4 yr	5 yr
Group A	48.3 (45.4-51.2)	82.6 (79.7-85.4)	87 (84.1-89.8)	87.7 (84.8-90.6)	88.4 (85.5-91.3)	88.6 (85.7-91.4)	87.7 (84.5-90.3)
Group B	46.4 (43.5-49.3)	58.7 (55.8-61.6)	57.8 (54.9-60.7)	57.7 (54.8-60.6)	58.4 (55.5-61.3)	57.7 (54.8-60.6)	56.3 (53.4-59.1)
<i>P</i> value	.428	<.001	<.001	<.001	<.001	<.001	<.001
Statistical significance	No	Yes	Yes	Yes	Yes	Yes	Yes

NOTE. Analysis was performed with the analysis of variance test. Mean values (95% CIs) are reported.

significantly increase from before surgery compared with after surgery. The score associated with the item “walking distance” (maximum score, 11) increased from a mean of 7 preoperatively to a mean of 10 in group A and 8.5 in group B. Table 3 reports the scores for pain and walking distance, with 95% CIs and the *P* values between the 2 groups.

### Complications

Unsatisfactory results were obtained in 3 cases in group A, with a mean HHS of 74.8 (95% CI, 73.3 to 76.5). In 1 case the cartilage defect was located on the superior area of the femoral head, and in 2 cases the defect was located both on the superior area of the femoral head and on the superior and anterior area of the acetabulum with joint space narrowing on standard radiographs. The worst results in group B were found in 4 patients with a cartilage lesion of more than 3 cm<sup>2</sup> located on the acetabulum. In these 4 patients the mean postoperative HHS was 51.5 (95% CI, 49.7 to 53.2). Calf-vein thrombosis developed at 2 weeks in 1 patient in group A and was treated by anticoagulants. A transient neurapraxia of the pudendal nerve developed in 1 patient in group B.

### DISCUSSION

Our results suggest several comments. First, the higher HHS at the final clinical evaluation of the

patients treated with ACT indicated a better outcome of this technique compared with simple debridement. This suggests the effectiveness of the technique in terms of pain relief. The role of ACT is unclear in postponing the progression of the arthritic process, as well as in terms of the lack of radiologic progression and the generation of cartilage. In addition, it must be noted that the postponement of the progression of the arthritic process is true only for the selected samples, as underlined later among the limitations. In addition, the results are based on clinical data, and there is no proof that the scaffold turned into cartilage. Postoperative radiographs, which we did not obtain, could have been helpful in clarifying these aspects. Second-look arthroscopy and MRI would have improved the value of the results. However, the former is not possible for ethical reasons, whereas the latter should be taken into consideration for further studies and further follow-up.

We do not think that the difference in the results could have been somehow related to the difference in weight bearing, which was allowed 2 weeks earlier in the debridement group. This protocol was decided on with the sole intent of protecting the scaffold and preventing its mobilization. The lower the starting HHS, the more unsatisfactory was the result, regardless of the technique used. As far as the treatment of hip chondropathies by use of arthroscopic debridement is concerned, this method shows scarce effec-

**TABLE 3.** *Scores for Main Items of HHS (Pain and Walking Distance)*

	Preoperative		Postoperative	
	Group A	Group B	Group A	Group B
Pain score (maximum, 44)	20 (18.7-21.38)	20 (18.9-21.1)	40 (38.6-41.4)	35 (33.2-36.8)
<i>P</i> value for pain score		>.9999		.0002
Walking distance score (maximum, 11)	7 (5.8-8.2)	7 (5.7-8.1)	10 (9.4-10.5)	8.5 (7.6-9.4)
<i>P</i> value for walking distance score		>.9999		.1115

NOTE. Mean values (95% CIs) are reported, along with *P* values comparing the 2 groups.

tiveness. The worst results were recorded in cases with a chondral defect equal to or greater than 3 cm<sup>2</sup>, as already indicated.<sup>15,32</sup> The clinical result of debridement is inversely proportional to the extension of the cartilage defect.<sup>32</sup> For these reasons, we believe that in those cases where radiographic signs of osteoarthritis are present, along with a reduction in the joint space, the ACT technique is not indicated. The lack of surrounding cartilage makes the creation of stable, clear margins impossible, with the “shoulder” clearly delineated, which is fundamental for greater stability. In addition, the geometric deformity of the femoral head, caused by the arthritic degeneration, does not guarantee the articular congruity required for implant stability. Moreover, this articular congruity in cases of arthritis is even more compromised by the acetabular labrum degeneration, which represents a fundamental element for both maintaining the negative intra-articular pressure and stabilizing the coxofemoral articulation.<sup>19,22</sup>

Hip arthroscopy, though considerably less common than knee arthroscopy, allows for chondropathies in this joint to be detected<sup>33</sup>; however, the therapeutic approach is different from the knee, because the hip is a deep articulation surrounded by large muscular masses that make surgical access difficult. Nevertheless, hip arthritis is highly limiting for patients, and a surgical procedure that has the potential to postpone its progression is of great interest. Hip arthrotomy exposes the articulation to the serious risk of aseptic necrosis of the femoral head, along with being a significantly invasive procedure. The arthroscopic approach to treating hip chondropathies therefore solves the serious problem associated with arthrotomy.

A critical point regarding the ACT performed by hip arthroscopy is implant stability. The various techniques used in the knee, both by arthrotomy and by arthroscopy,<sup>2-6</sup> might be difficult to use in the hip. Recently, a minimally invasive technique for ACT of the knee that could be applied to the hip was suggested.<sup>34</sup> The efficacy of ACT techniques is well supported in the literature,<sup>35,36</sup> and the application to the hip is attractive. Some points of the surgical technique should be pointed out: Performing a chondrectomy with wide exposure of the subchondral bone and the creation of clear margins allows for greater stability of the implant on the acetabulum. This stability is reinforced by the geometric and physical properties featured by the hip.

The scaffold used in this study as a support for the cellular transplant features intrinsic rigidity that maintains a structural “memory.” This polymer, rolled and

inserted through the arthroscopic cannula, then unfolds and returns to its original 3-dimensional shape once it has reached the articular cavity. This allows for it to easily adapt to the concave surface of the acetabulum that needs to be covered. As shown in Fig 2, which shows the membrane in a gas environment, we turned off the fluid inflow during graft delivery and placement. We believe this is helpful for positioning the graft at its site.

The scaffold was chosen without any particular selection criteria. It is possible that several other scaffolds and material may have the same properties and therefore can be used for such implantations. It is not our intention to suggest a specific scaffold, and further comparative studies with different scaffolds would be necessary to determine the effectiveness of 1 material compared with other materials. The femoral head, together with the negative intra-articular pressure, represents an effective biologic mechanism for stabilizing the transplant on the acetabular cavity. A study carried out on cadavers showed that the stability of the scaffold implanted on cartilage defects of the acetabulum varies from 80% to 83.3% of the cases (A.F., unpublished data, December 2004). In theory, the stability of the membrane in the concave acetabular surface is greater than that on the convex surface of the femoral head (Fig 4). In addition, the pressure of the femoral head against the acetabulum and the sharp margins of the chondral lesion obtained by accurate chondrectomy contribute to the stability of the transplant. The situation regarding cartilage defects of the femoral head is different. In fact, on these convex surfaces, the same physical properties featured by the scaffold used in this study prove to be a disadvantage in terms of implant stability. Because the scaffold is rigid, it is less adaptable to the area that requires the transplant because the transplant margins tend to extend beyond the margins of the lesion. This explains why we suggest implant placement on the acetabulum and not on

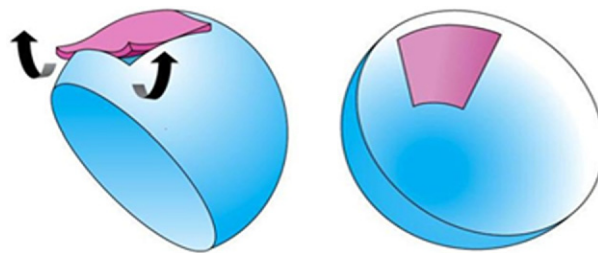


FIGURE 4. Intrinsic instability on femoral head because of sphericity and intrinsic stability of membrane because of concavity of acetabulum.

the femoral head. The use of a device to fix the implant in place, such as bioabsorbable nails or pins, might also be considered in further studies. In addition, the use of microfracture technique must be considered in further studies for creating the control group. Moreover, microfractures can be used in combination with a scaffold without the cultivation of chondrocytes. In this case the scaffold would act as a support and a growth environment for the mesenchymal cells provided by the microfractures. This work illustrates the feasibility of using a scaffold intraoperatively, but whether the addition of chondrocytes is necessary and the success of seeding the scaffold with autologous cells remain unclear and require further specific studies. In addition, this work focuses on the treatment of chondral lesions localized in the acetabulum, whereas femoral lesions are not suitable for such treatment.

This study was limited by the reduced number of patients, the lack of an objective method for the evaluation of the results (i.e., radiographic data, second-look arthroscopy, or MRI), and the lack of power analysis. Other limitations are the criteria for patient inclusion, selection bias in the randomization process, and the lack of comparison to microfracture technique. Another limitation is the availability of the patch in the United States and other markets. However, we think that other materials could be used.

## CONCLUSIONS

The main aim of this study was to suggest that an ACT procedure can be used in the hip for acetabular chondral defects. The findings of the study suggest that ACT may be an option for cartilage defects of the hip joint.

**Acknowledgment:** The first author (A.F.) thanks Mr. Villar for training and assistance in performing the hip arthroscopy surgical technique.

## REFERENCES

1. Steadman JR, Rodkey WG, Rodrigo JJ. Microfracture: Surgical technique and rehabilitation to treat chondral defects. *Clin Orthop Relat Res* 2001;362-369 (Suppl).
2. Gooding CR, Bartlett W, Bentley G, Skinner JA, Carrington R, Flanagan A. A prospective, randomised study comparing two techniques of autologous chondrocyte implantation for osteochondral defects in the knee: Periosteum covered versus type I/III collagen covered. *Knee* 2006;13:203-210.
3. Briggs TWR, Mahroof S, David LA, Flannelly J, Pringle J, Bayliss M. Histological evaluation of chondral defects after autologous chondrocyte implantation of the knee. *J Bone Joint Surg Br* 2003;85:1077-1083.
4. Erggelet C, Sittlinger M, Lahm A. The arthroscopic implantation of autologous chondrocytes for the treatment of full-thickness cartilage defects of the knee joint. *Arthroscopy* 2003;19:108-110.
5. Kreuz PC, Müller S, Ossendorf C, Kaps C, Erggelet C. Treatment of focal degenerative cartilage defects with polymer-based autologous chondrocyte grafts: Four-year clinical results. *Arthritis Res Ther* 2009;11:R33.
6. Brittberg M, Lindahl A, Nilsson A, Ohlsson C, Isaksson O, Peterson L. Treatment of deep cartilage defects in the knee with autologous chondrocyte transplantation. *N Engl J Med* 1994;331:889-895.
7. Gomoll AH, Farr K. Future developments in cartilage repair. In: Cole BJ, Gomoll AH, eds. *Biologic joint reconstruction, alternative to arthroplasty*. Thorofare: Slack, 2009;163-168.
8. Chang KY, Cheng LW, Ho GH, Huang YP, Lee YD. Fabrication and characterization of poly(gamma-glutamic acid)-graft-chondroitin sulfate/polycaprolactone porous scaffolds for cartilage tissue engineering. *Acta Biomater* 2009;5:1937-1947.
9. Knecht S, Erggelet C, Endres M, Sittlinger M, Kaps C, Stussi E. Mechanical testing of fixation techniques for scaffold-based tissue-engineered grafts. *J Biomed Mater Res B Appl Biomater* 2007;83:50-57.
10. Steinwachs MR, Gugli T, Kreuz PC. Marrow stimulation techniques. *Injury* 2008;39:26-31.
11. Gigante A, Bevilacqua C, Ricevuto A, Mattioli-Belmonte M, Greco F. Membrane-seeded autologous chondrocytes: Cell viability and characterization at surgery. *Knee Surg Sports Traumatol Arthrosc* 2007;15:88-92.
12. Steinwachs M, Kreuz PC. Autologous chondrocyte implantation in chondral defects of the knee with a type I/III collagen membrane: A prospective study with a 3-year follow-up. *Arthroscopy* 2007;23:381-387.
13. Gobbi A, Bathan L. Minimally invasive second generation autologous chondrocyte implantation. In: Cole BJ, Gomoll AH, eds. *Biologic joint reconstruction, alternative to arthroplasty*. Thorofare: Slack, 2009;155-161.
14. Iwasa J, Engebretsen L, Shima Y, Ochi M. Clinical application of scaffolds for cartilage tissue engineering. *Knee Surg Sports Traumatol Arthrosc* 2009;17:561-577.
15. McCarthy JC, Lee J. Hip arthroscopy: Indications and technical pearls. *Clin Orthop Relat Res* 2005;441:180-187.
16. Tibor LM, Sekiya JK. Differential diagnosis of pain around the hip joint. *Arthroscopy* 2008;24:1407-1421.
17. Ganz R, Parvizi J, Beck M, Leunig M, Nötzli H, Siebenrock KA. Femoroacetabular impingement: A cause for osteoarthritis of the hip. *Clin Orthop Relat Res* 2003;412:112-120.
18. Beck M, Kallhor M, Leunig M, Ganz R. Hip morphology influences the pattern of damage to the acetabular cartilage: Femoroacetabular impingement as a cause of early osteoarthritis of the hip. *J Bone Joint Surg Br* 2005;87:1012-1018.
19. Konrath GA, Hamel AJ, Olson SA, Bay B, Sharkey NA. The role of the acetabular labrum and the transverse acetabular ligament in load transmission in the hip. *J Bone Joint Surg Am* 1998;80:1781-1788.
20. Byrd JW. Labral lesions: An elusive source of hip pain case reports and literature review. *Arthroscopy* 1996;12:603-612.
21. Cartlidge IJ, Scott JH. The intumed acetabular labrum in osteoarthritis of the hip. *J R Coll Surg Edinb* 1982;27:339-344.
22. Harris WH, Bourne RB, Oh J. Intra-articular acetabular labrum: A possible etiological factor in certain cases of osteoarthritis of the hip. *J Bone Joint Surg Am* 1979;61:510-514.
23. McCarthy JC, Noble PC, Schuck MR, Wright J, Lee J. The Otto E. Aufranc Award: The role of labral lesions to develop-

- ment of early degenerative hip disease. *Clin Orthop Relat Res* 2001;25-37.
24. McCarthy JC, Noble PC, Schuck MR, Aluisio FV, Wright J, Lee J. Acetabular and labral pathology. In: McCarthy JC, ed. *Early hip disorders*. Chapter 12. New York: Springer-Verlag, 2003:113-134.
  25. Yen YM, Kocher MS. Chondral lesions of the hip: Microfracture and chondroplasty. *Sports Med Arthrosc* 2010;18:83-89.
  26. Haviv B, Singh PJ, Takla AK, O'Donnell J, Kulkarni MG, Nayak P. Arthroscopic femoral osteochondroplasty for cam lesions with isolated acetabular chondral damage. *J Bone Joint Surg Br* 2010;92:629-633.
  27. Wright TM, Maher SA. Current and novel approaches to treating chondral lesions. *J Bone Joint Surg Am* 2009;91:120-5 (Suppl 1).
  28. Philippon MJ, Schenker ML, Briggs KK, Maxwell RB. Can microfracture produce repair tissue in acetabular chondral defects? *Arthroscopy* 2008;24:46-50.
  29. Crawford K, Philippon MJ, Sekiya JK, et al. Microfracture of the hip in athletes. *Clin Sports Med* 2006;25:327-335.
  30. Barber FA, Iwasko NG. Treatment of grade III femoral chondral lesions: Mechanical chondroplasty versus monopolar radiofrequency probe. *Arthroscopy* 2006;22:1312-1317.
  31. Tzaveas AP, Villar RN. Arthroscopic repair of acetabular chondral delamination with fibrin adhesive. *Hip Int* 2010;20:115-119.
  32. Glick JM. Hip arthroscopy using the lateral approach. *Instr Course Lect* 1988;37:223-231.
  33. Santori N, Villar RN. Arthroscopic findings in the initial stages of hip osteoarthritis. *Orthopedics* 1999;22:405-409.
  34. Anders S, Schaumburger J, Schubert T, Grifka J, Behrens P. Matrix-associated autologous chondrocyte transplantation (MACT). Minimally invasive technique in the knee. *Oper Orthop Traumatol* 2008;20:208-219 (in German).
  35. Batty L, Dance S, Bajaj S, Cole BJ. Autologous chondrocyte implantation: An overview of technique and outcomes. *ANZ J Surg* 2011;81:18-25.
  36. Strauss EJ, Fonseca LE, Shah MR, Yorum T. Management of focal cartilage defects in the knee—Is ACI the answer? *Bull NYU Hosp Jt Dis* 2011;69:63-72.

**ABSTRACTS IN SPANISH!**

**¡RESÚMENES AL ESPAÑOL!**

**are now available at [www.arthroscopyjournal.org](http://www.arthroscopyjournal.org)**

**Subscribers can access from the Table of Contents by clicking "Supplemental Materials." Nonsubscribers can access the Spanish Abstracts by issue for free from the home page.**